

· Case Report ·

Persistent Muellierian duct syndrome with transverse testicular ectopia

Yue-You Liang, Fu-Fu Zheng, Yu-Ping Dai, Ke-Li Zheng, Jie-Xue Zhou

Department of Urology, The First Affiliated Hospital, Sun Yat-Sen University, Guangzhou 510080, China

Abstract

Persistent Muellierian duct syndrome (PMDS) is a rare form of male pseudohermaphroditism without the feature of ambiguous genitalia. We present a case of PMDS with transverse testicular ectopia (TTE). (*Asian J Androl* 2006 Nov; 8: 745–747)

Keywords: pseudohermaphroditism; persistent Muellierian duct syndrome; transverse testicular ectopia

1 Case report

A 44-year-old man who had fathered four children presented to our hospital (The First Affiliated Hospital, Sun Yat-Sen University, Guangzhou, China) with a right inguinal-scrotal hernia, left cryptorchidism and hydrocele of the tunica vaginalis that had been discovered during surgical exploration in another hospital. He had been referred to our institution for further evaluation and treatment. Physical examination revealed left cryptorchidism, a right inguinal mass, a normal scrotum, a well-formed penis and unpalpable testes in the right hemiscrotum. A digital rectal examination (DRE) showed a normal prostate, and transillumination test was negative. The level of testosterone (6.57 ng/mL), alpha-fetoprotein (AFP)(1.83 µg/L) and human chorionic gonadotrophin (HCG)(1.20 IU/L) in sera were within the normal ranges. Peripheral blood leukocyte chromosome analysis revealed the patient to be a

normal male of karyotype 46,XY. Semen analysis was normal. An abdominal ultrasound showed a hydrocele in the tunica vaginalis; two testicles were located at the right hemiscrotum; the left-inguinal and pelvic cavity had no testicle. Magnetic resonance imaging (MRI) had been done but the pelvic genital organs were not found. On a second surgical exploration, a vas deferens, uterine tubes and a uterus were found within the hernia. Histological analysis confirmed the presence of rudimentary internal female genitalia and testes were identified but not ovarian

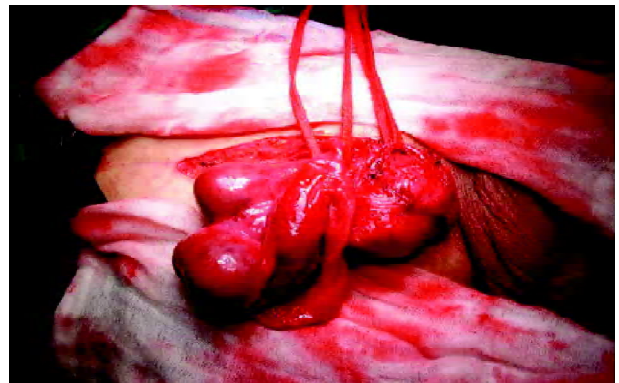


Figure 1. Both testicles located at the right hemiscrotum.

Correspondence to: Fu-Fu Zheng, Department of Urology, The First Affiliated Hospital, Sun Yat-Sen University, Guangzhou 510275, China.

Tel: +86-208-7755-766 ext 8227, Fax: +86-208-7333-300

E-mail: zffcnj@163.com

Received 2004-12-29 Accepted 2005-06-23

testes. Both testicles were located at the right hemiscrotum (Figure 1). The diagnosis was Persistent Mullerian duct syndrome (PMDS) with transverse testicular ectopia (TTE). Corrections of the hydrocele and the herniorrhaphy were performed simultaneously and the uterine tubes and the uterus were partly removed. Two months later, the hydrocele of the tunica vaginalis disappeared.

2 Discussion

Male pseudohermaphroditism is defined as an individual with bilateral testicles, a normal male karyotype, but with either ambiguous internal genital ducts or external genitalia or the persistence of Mullerian structures [1]. PMDS is a rare form of male pseudohermaphroditism characterized by the persistence of the uterus and fallopian tubes and the incomplete regression of the Mullerian duct in an otherwise normally virilized male. This condition is caused by a defect in the synthesis or receptor of the Mullerian-inhibiting substance (MIS), also known as the anti-Mullerian hormone (AMH) and the Mullerian-inhibiting factor (MIF) [2–5]. MIS is a 145-kDa glycoprotein produced by immature Sertoli cells and is responsible for the regression of Mullerian ducts in male fetuses and the anlagen of the fallopian tubes and the uterus in females. It binds to a specific type II serine-threonine kinase transmembrane receptor (MISR-II). The human *MIS* gene consists of five exons: 412, 124, 108, 160 and 856 bp in length and is localized near the tip of chromosome 19, in subbands 13.2 to 13.3. Mutations of the *MIS* gene or the *MISR-II* gene have been identified in PMDS patients with autosomal recessive transmission [6–9]. PMDS often occurs in karyotypic (46, XY) males. Two kinds of hormones produced by the fetal testis mediate the differentiation of the Mullerian and Wolffian ducts. MIS actively inhibits the development of the Mullerian ducts, and its absence leads to the development of the fallopian tubes, uterus and the proximal vagina. Testosterone produced by Leydig cells induces a differentiation of the Wolffian ducts, which forms the vas deferens, epididymis and the seminal vesicles. The absence of these two hormones during fetal development in female permits Mullerian duct differentiation and regression of the Wolffian duct. PMDS is incidentally discovered during herniorrhaphy, orchidopexy or abdominal exploration for other reasons, such as unilateral or bilateral inguinal hernia with cryptorchidism and Mullerian duct remnants presenting as an inguinal mass

(classical hernia uterine inguinalis), pelvic testes in a peri-uterine position or TTE with or without inguinal hernia [10,11]. The main reasons of cryptorchidism are the roles of MIS and the presence of remnant Mullerian structures can further hinder testicular descent mechanically [12]. Although virilization is generally unaffected in patients with PMDS, infertility is common. However, this patient's semen analysis was normal and 2 months postoperation, repeated semen analysis, sperm count and motility were all still normal. Only two of the 10 reported cases of PMDS with TTE featured fertile patients [1, 13]. The cause, we think, may be partly the resistance or insensitivity of the MIS-receptor to MIS. Testicular function in this case was not impaired. Of course, the real reasons need to be explored further. The accurate diagnosis of PMDS is made by histological analysis, karyotype and the detection of MIS. In treating PMDS, it is recommended that the testicles be descended at an early stage if possible, or otherwise removed if there is a high risk of testicular malignancy. If lifelong testosterone substitution is needed, we adopt efficient patient monitoring, which requires good patient compliance. The remnant Mullerian structures are left *in situ* because they are asymptomatic situation. If there are symptoms (e.g. recurrent infections, abscess formation or voiding difficulties), the structures need to be removed.

References

- 1 Berkmen F. Persistent Mullerian duct syndrome with or without transverse testicular ectopia and testis tumours. *Br J Urol* 1997; 79: 122–6.
- 2 Ferri M, Ansari S, deMaria J. Persistent Mullerian duct syndrome associated with transverse testicular ectopia. *Can J Urol* 1999; 6: 865–7.
- 3 Buchholz NP, Biyabani R, Herzig MJ, Ali A, Nazir Z, Sulaiman MN, *et al.* Persistent Mullerian duct syndrome. *Eur Urol* 1998; 34: 230–2.
- 4 Meyers-Wallen VN, Donahoe PK, Ueno S, Manganaro TF, Patterson DF. Mullerian inhibiting substance is present in testes of dogs with persistent mullerian duct syndrome. *Biol Reprod* 1989; 41: 881–8.
- 5 Lima M, Domini M, Libri M. Persistent mullerian duct syndrome associated with transverse testicular ectopia: a case report. *Eur J Pediatr Surg* 1997; 7: 60–2.
- 6 Halbertsma FJ, Otten BJ, Wijnen RM, Feitz WF. A baby boy with cryptorchism, inguinal hernia and internal female genitalia: the persistent Mullerian duct syndrome. *Ned Tijdschr Geneesk* 2004; 148: 484–7.
- 7 Hoshiya M, Christian BP, Cromie WJ, Kim H, Zhan Y, MacLaughlin DT, *et al.* Persistent Mullerian duct syndrome caused by both a 27-bp deletion and a novel splice mutation in the MIS

- type II receptor gene. *Birth Defects Res Part A Clin Mol Teratol* 2003; 67: 868-74.
- 8 Jarminska-Jackowiak T, Warenik-Szymankiewicz A, Trzeciak WH. Anti-Mullerian hormone. Structure and role in sexual differentiation. *Ginekol Pol* 1995; 66: 51-8.
 - 9 Loeff DS, Imbeaud S, Reyes HM, Meller JL, Rosenthal IM. Surgical and genetic aspects of persistent mullerian duct syndrome. *J Pediatr Surg* 1994; 29: 61-5.
 - 10 Picard JY, Belville C. Genetics and molecular pathology of anti-Mullerian hormone and its receptor. *J Soc Biol* 2002; 196: 217-21.
 - 11 Meyers-Wallen VN, Lee MM, Manganaro TF, Kuroda T, Maclaughlin D, Donahoe PK. Mullerian inhibiting substance is present in embryonic testes of dogs with persistent mullerian duct syndrome. *Biol Reprod* 1993; 48: 1410-8.
 - 12 Asero L, Meli R. The persistent mullerian duct syndrome with transverse testicular ectopia. A hypothesis on the role of mullerian inhibiting factor in the process of testicular migration. *Pediatr Med Chir* 1997; 19: 223-5.
 - 13 Weiss EB, Kiefer JH. Persistent mullerian duct syndrome in male identical twins. *Pediatrics* 1978; 61: 797-800.

Edited by Shao-Zhen Qian