

Original Article

Effect of hydrocele on appendix testis in children

Tamás Józsa^{1,2}, Andrea Telek³, Balázs Kutasy¹, Mátyás Benyó², Gábor Csanádi², Ilona Kovács⁴, György Balla¹, Tibor Flaskó², László Csernoch³, Csongor Kiss¹

¹Department of Pediatrics, Medical and Health Science Center, University of Debrecen, Debrecen 4032, Hungary

²Department of Urology, Medical and Health Science Center, University of Debrecen, Debrecen 4032, Hungary

³Department of Physiology, Medical and Health Science Center, University of Debrecen, Debrecen 4032, Hungary

⁴Department of Pathology, Kenézy Gyula County Hospital, Debrecen 4032, Hungary

Abstract

The purpose of this study was to investigate the effects of an elevated hydrostatic pressure of hydrocele on the structural integrity and steroid receptor expression pattern of the appendix testis in children. Twenty-six testicular appendages were obtained from boys (aged between 13 and 79 months, mean 40 months) who underwent surgical exploration because of hydrocele or congenital inguinal hernia. The tissue sections of testicular appendages were stained with hematoxylin-eosin. Immunohistochemistry and immunofluorescence laser microscopy were performed using monoclonal mouse anti-human receptors against androgen and estrogen receptors. Patients were divided into three groups: group A ($n = 8$) represented patients with groin hernia without hydrocele, who served as control group; group B ($n = 7$) represented patients with communicating hydrocele; and group C ($n = 11$) represented patients with noncommunicating hydrocele. The tissue sections of appendix testis expressed both androgen and estrogen receptors in all patients in groups A and B, and epithelial destruction was not present. The presence of androgen receptor (two of 11, $P < 0.001$) and estrogen receptor (four of 11, $P = 0.006$) was lower and the number of appendix testes with epithelial destruction was higher (eight of 11, $P = 0.001$) in group C. We demonstrated that groin hernia and communicating hydrocele did not influence the receptor expression pattern and the anatomic structure of testicular appendages, whereas noncommunicating hydrocele caused damage as indicated by the absence of steroid receptors and destruction of the epithelial surface. A better understanding of the physiological role of testicular appendages may change the indications of surgical treatment in patients with noncommunicating hydrocele.

Asian Journal of Andrology (2009) 11: 741–745. doi: 10.1038/aja.2009.54; published online 28 September 2009.

Keywords: androgen receptor, appendix testis, estrogen receptor, hydrocele

1 Introduction

Hydrocele is defined as an accumulation of fluid

between the parietal and visceral layers of the tunica vaginalis [1]. The incidence of hydrocele among male infants is unknown. Hydroceles in children are categorized into two different types, communicating and noncommunicating (simple scrotal) hydroceles. It is widely accepted that, because of the tendency for spontaneous resolution, surgical treatment of hydroceles in children below 1 year of age is not recommended [2, 3]. Persistence of a simple scrotal hydrocele beyond

Correspondence to: Dr Tamás Józsa, DE OEC Gyermekklinika, 4012 Debrecen, Nagyerdei krt. 98, Hungary.

Fax: +36-5241-4992 E-mail: jozsa_tamas@freemail.hu

Received: 17 March 2009 Revised: 21 April 2009

Accepted: 6 August 2009 Published online: 28 September 2009



12–24 months of age may be an indication for surgical correction. However, a risk of testicular damage associated with this type of hydrocele remains to be determined.

There have been only a small number of investigations assessing the effect of hydrocele on the functional and structural integrity of testicles. Few reports investigating adult patients have shown that hydroceles may impair spermatogenesis and induce structural damages. Dandapat *et al.* [4] reported the arrest of spermatogenesis in about 20% of patients with large hydroceles. The histopathological changes observed were interstitial fibrosis, thickening of the basement membrane and disorganization of spermatogenic cells [4, 5].

The appendix testis (AT) (also known as hydatid of Morgagni) is the vestigial remnant of the paramesonephric (Müllerian) duct, located at the upper pole of the testis or in the groove between the testis and the epididymis [6]. The physiological role of this remnant remains to be determined. However, some investigators assume possible functions of AT in humans. AT may control the amount of serous fluid within the space of tunica vaginalis [7]. Another hypothesis suggested that the surface epithelium, subepithelial capillaries and lymphatic vessels of AT form a functional unit [8]. To avoid the risk of AT torsion, a search and elective excision is recommended in the course of intrascrotal intervention in children [9]. The removal of ATs provides an opportunity to evaluate the possible histomorphological and functional changes induced by an elevated hydrostatic pressure in hydroceles.

In 2003, Samnakay *et al.* [10] described the expression of androgen receptors (ARs) and estrogen receptors (ERs) in the epithelial lining of human ATs. In our previous study, we found a significant difference between the AR status of ATs in descended and undescended testicles [11]. To examine a possible influence of the elevated hydrostatic pressure present in hydroceles, we investigated the structural integrity of ATs and the AR and ER expression pattern of AT in hydroceles in a retrospective analysis of excised ATs.

2 Materials and methods

2.1 Patient selection

Twenty-six ATs were collected from boys undergoing surgical exploration because of hydrocele or congenital inguinal hernia at the Surgical Ward of the Department

of Pediatrics, University of the Medical and Health Science Center, University of Debrecen (MHSCUD). The testicles were visible in the course of surgical intervention. The age of the patients ranged from 13 to 79 months (mean 40 months).

Patients were divided into three groups. Group A included eight boys (mean age 41 months) undergoing hernioplasty due to groin hernia. Group B included seven boys (mean age 35 months) operated on because of communicating hydrocele. The mean interval between the first presentation of symptoms and the operation was 38 months. Group C included 11 boys (mean age 41 months) operated on because of noncommunicating hydroceles. The mean interval between the first presentation of symptoms and operation was 5 months.

Communicating and noncommunicating hydroceles were defined as follows: communicating hydroceles were characterized by excessive fluid accumulation within the tunica vaginalis that changed in size according to history (reduction in size during sleep/early morning and increase in size during the course of the day) or on physical examination. Noncommunicating hydroceles were characterized by excessive fluid accumulation within the tunica vaginalis that did not change in size according to history or on physical examination, and at the time of physical examination, the fluid could not be expressed from the scrotum [2]. However, noncommunicating hydroceles vary in pressure; we found all of our cases with noncommunicating hydroceles to be tense. The operative treatment was the ligation of the persisting or obliterated processus vaginalis of the peritoneum and the wide opening of the tunica vaginalis around the testis. ATs, when present, were removed in the course of the operation. The study protocol was approved by the Ethics Committee of MHSCUD. Written informed consent was obtained from parents or guardians before the children were enrolled into the study.

2.2 Histology

Formalin-fixed, paraffin-embedded tissue sections of excised ATs were stained with hematoxylin-eosin (HE). Two blinded, independent pathologists evaluated the slides to confirm the diagnosis and to assess the destruction of the epithelial surface.

2.3 Immunohistochemistry

Formalin-fixed, paraffin-embedded tissue sections of excised ATs were stained for AR and ER using a

mouse monoclonal anti-human AR antibody (clone F39.4.1, BioGenex, San Ramon, CA, USA) and a mouse monoclonal anti-human ER antibody (clone 1D5, DAKO, Glostrup, Denmark), according to the method described previously [6]. Visualization was performed using diamino-benzidine. The following controls were used: the positive control was a prostate cancer tissue for AR and a breast cancer tissue for ER. For negative controls, parallel sections of each sample were used omitting the primary antibody. The sections were evaluated under a light microscope with an incorporated photography system (Leica DM 2500, DFC 480, Leica Microsystem, Heerbrugg, Switzerland) at $\times 10$, $\times 20$ and $\times 40$ magnifications. Brown nuclear staining for AR and ER in the epithelial surface and/or in the epithelial lining of the acini was considered positive.

2.4 Laser-scanning confocal microscopy

After incubation with the above primary antibodies, sections were stained with the fluorescein isothiocyanate-conjugated goat anti-mouse secondary antibody (1:500, Vector Laboratories, Burlingame, USA) for 451 min in room temperature. Sections were counterstained with 4',6-diamidino-2-phenylindole (Vector Laboratories). As negative controls, the appropriate primary antibody was either omitted from the procedure or was preincubated with a synthetic blocking peptide. Receptors were imaged using the LSM 510 laser-scanning confocal microscope (Zeiss, Oberkochen, Germany) with an $\times 63$ water immersion objective (1.2 NA; Zeiss). Green fluorescence nuclear staining for AR and ER in the epithelial surface and/or in the epithelial lining of the acini was considered as a positive reaction.

2.5 Statistics

The presence of AR and ER with immunohistochemical and immunofluorescence stainings and the

destruction of the epithelial surface of the AT judged on HE-stained sections were analyzed in all groups. Fisher's exact test was used for all statistical analyses. $P < 0.05$ was considered statistically significant for all parameters.

The duration of existence of hydrocele between the first presentation of symptoms and surgical treatment was registered retrospectively from the patient's medical charts.

3 Results

Details regarding the presence of AR, ER and epithelial destruction are summarized in Table 1. Histological evaluation of the HE-stained slides showed that there was no epithelial destruction in either group A or group B, but a serious lesion with the absence of more than half of the epithelial layer was found in eight of 11 patients in group C (Figure 1). The tissue sections of ATs expressed both AR and ER in all patients of group A and group B as confirmed by both immunohistochemistry and immunofluorescence staining (Figure 2). The number of AR-positive

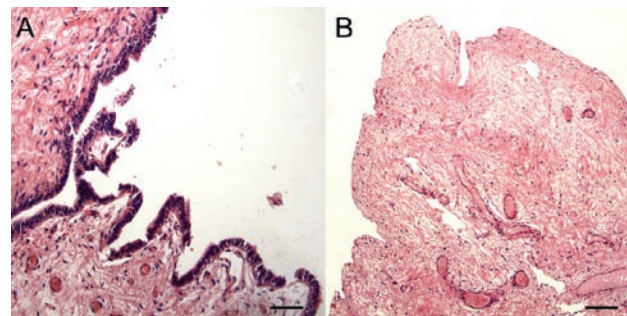


Figure 1. Hematoxylin-eosin staining of the normal epithelial layer of AT excised (A) from a patient with groin hernia and destruction of the epithelial layer, and (B) from a patient with noncommunicating hydrocele (Bar = 100 μm) (magnification: $\times 20$).

Table 1. Androgen and estrogen receptor (AR and ER) expression and signs of epithelial damage in testicular appendices (AT) of three different groups of patients.

Group	Presence of androgen receptor ($P < 0.001$)	Presence of estrogen receptor ($P = 0.006$)	Epithelial destruction ($P = 0.001$)
Congenital groin hernia (group A)	8 ($n = 8$)	8 ($n = 8$)	0 ($n = 8$)
Communicating hydrocele (group B)	7 ($n = 7$)	7 ($n = 7$)	0 ($n = 7$)
Non-communicating hydrocele (group C)	2 ($n = 11$)	4 ($n = 11$)	8 ($n = 11$)

samples and that of ER-positive samples were lower (AR positive 2 of 11, $P < 0.001$, ER positive 4 of 11, $P = 0.006$) in group C. Figure 3 demonstrates the negative immunohistochemical and immunofluorescence staining in a representative noncommunicating hydrocele sample.

The interval between the first presentation of symptoms and the operation was 3 weeks and 4 weeks, respectively, in the two AR-positive ATs of group C. In the nine AR-negative samples, noncommunicating hydrocele persisted for at least 1 month (range 1 month–36 months, mean 7 months). Eight of these patients with noncommunicating hydrocele exhibited some kind of epithelial damage in the AT; hydrocele in those cases persisted over 1 month. Similar observations were made with respect to ER expression in this group of patients. Hydrocele in 7 of 11 ER-negative cases persisted over 1 month and ER negativity was accompanied by signs of epithelial destruction.

4 Discussion

Most cases of simple scrotal hydroceles presenting

at birth do not require surgical treatment as they tend to resolve spontaneously during the first 2 years of life. In these cases, the usual attitude is the watch-and-wait approach. The most frequent indications for surgery of pediatric hydroceles are (1) hydroceles complicated by an inguinal hernia or cryptorchidism; (2) hydroceles that presented at an older age and did not resolve over a period of 2–3 years; (3) giant communicating funicular and testicular hydroceles that impair the quality of life [12].

Tanyel *et al.* [13] found that the mean hydrocele pressure was higher than the intraabdominal pressure. They assumed that this increased pressure may damage testicles and other intrascrotal organs by the potential effects of compression exerted by the accumulated fluid in the tunica vaginalis. Indeed, testicular interstitial fibrosis, thickening of the basement membrane and disorganization of spermatogenic cells have been observed in adult patients with hydroceles [4, 5]. However, these potential complications are not included among the indications of surgical treatment of hydroceles. Our results demonstrated the absence of AR and ER in the majority of ATs in patients with

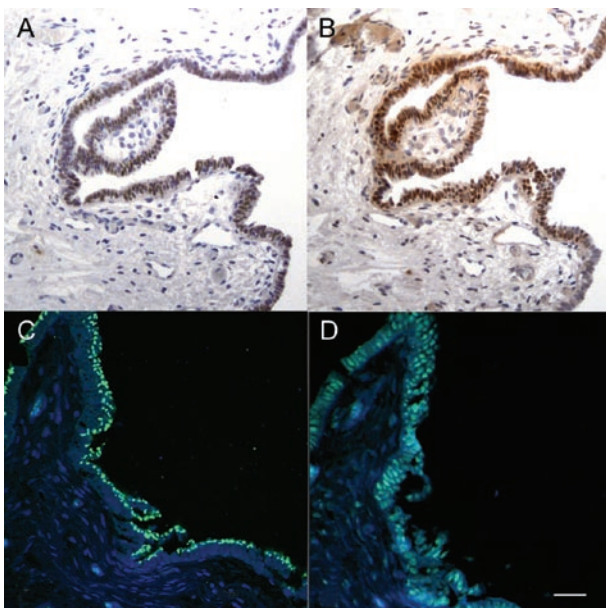


Figure 2. Androgen receptor (AR) (A) and estrogen receptor (ER) (B) expression in representative samples from a patient with groin hernia by immunohistochemistry (magnification: $\times 20$). AR (C) and ER (D) expression by immunofluorescence laser confocal microscopy in the epithelial surface of AT from a patient with groin hernia (Bar = 50 μm).

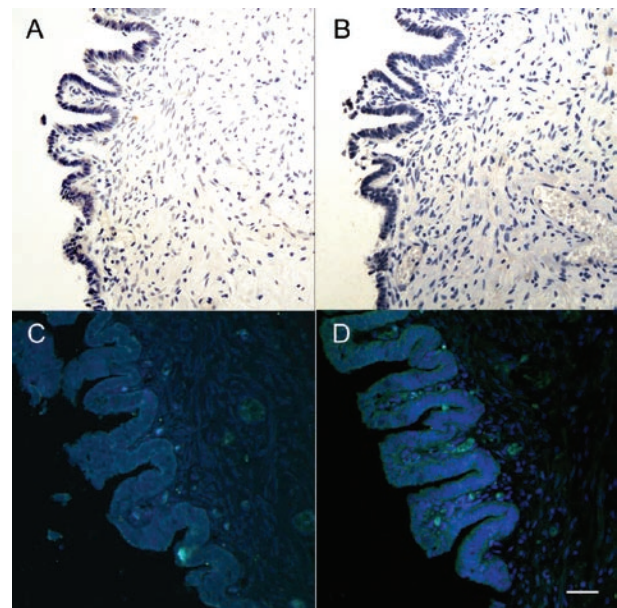


Figure 3. Absence of androgen receptor (AR) (A) and estrogen receptor (ER) expression (B) by immunohistochemistry (magnification: $\times 20$). Absence of AR (C) and ER expression (D) by immunofluorescence laser confocal microscopy in the epithelial surface of AT (Bar = 50 μm). A representative specimen was taken from a patient with noncommunicating hydrocele.

noncommunicating hydrocele. The lack of steroid receptor expression was accompanied by destructive changes in the epithelial layer of the investigated ATs. In contrast, these steroid receptors were always present and no epithelial destruction was observed in the ATs of patients with communicating hydrocele. These findings suggest that elevated hydrostatic pressure in the tunica vaginalis may impair the function and morphology not only of the testicular appendages but also of testicles. Our results also suggest that time may be an important factor of the untoward effects exerted by elevated hydrostatic pressure in patients with noncommunicating hydrocele.

Christensen *et al.* [2] found that approximately 75% of noncongenital, noncommunicating hydroceles resolve spontaneously, irrespective of size, within 5.6 months on an average. On the basis of this observation, they recommended an observation period of 6–12 months before surgical intervention. In contrast, we found that the majority of patients who have persisting noncommunicating hydrocele for at least 1 month suffered some kind of epithelial damage and lost steroid receptor expression in their testicular appendages.

It is difficult to examine the effect of noncommunicating hydrocele on the AR/ER status and on morphological changes of the testicles in children. Only biopsy could determine potential functional and morphological changes in the testis. If lesions observed in the ATs go hand in hand with testicular damage, serious harmful influences of increased hydrostatic pressure on the testicles of patients with long-lasting noncommunicating hydrocele cannot be ruled out. Therefore, damages of ATs may change our current position on the surgical indication of treating noncommunicating hydroceles. Further research is required to complete our understanding about the marker function of damages observed in ATs induced by elevated hydrostatic pressure with respect to testicular damage.

In conclusion, the persistence of noncommunicating hydrocele for at least 1 month resulted in the destruction of AT, indicated by the absence of AR and ER expression and by epithelial destruction. However, further studies are required to understand the functional significance of this phenomenon, in particular with regard to the parallel damages of testicular steroid receptors. Given the high rate of spontaneous resolution of

noncommunicating hydroceles in children, an altered epithelial AR/ER expression *per se* cannot be considered as an indication for subjecting children with hydrocele to surgery.

Acknowledgment

The authors thank Ms Erika Barna, Mrs Andrea Sósne Csik and Mr László Petromán for their excellent technical assistance.

References

- 1 Kapur P, Caty MG, Glick PL. Pediatric hernias and hydroceles. *Pediatr Clin N Am* 1998; 45: 773–89.
- 2 Christensen T, Cartwright PC, Devries C, Snow BW. New onset of hydroceles in boys over 1 year of age. *Int J Urol* 2006; 13: 1425–7.
- 3 Lau ST, Lee YH, Caty MG. Current management of hernias and hydroceles. *Semin Pediatr Surg* 2007; 16: 50–7.
- 4 Dandapat MC, Padhi NC, Patra AP. Effect of hydrocele on testis and spermatogenesis. *Br J Surg* 1990; 77: 1293–4.
- 5 Mangoud AM, Emara MW, Ghobish A, Khalil OM, Mossad A, *et al.* Hydrocele in filarial and non filarial patients. Histochemical, histochemical and ultrastructural studies. *J Egypt Soc Parasitol* 1993; 23: 43–54.
- 6 Atkinson GO Jr, Patrick LE, Ball TI Jr, Broecker BH, Woodard JR. The normal and abnormal scrotum in children: evaluation with color Doppler sonography. *Am J Roentgenol* 1992; 158: 613–7.
- 7 Jacob M, Berteczko K. Contribution to the origin and development of the appendices of the testis and epididymis in humans. *Anat Embryol* 2005; 209: 287–302.
- 8 Posinovec J. Is the unstalked hydatid a functioning organ? *Verh Anat Ges* 1969; 63: 751–9.
- 9 Anderson PJ, Kincaid R, Orr JD. Testicular appendages: incidence and clinical significance. *Pediatr Surg Int* 1995; 10: 118–9.
- 10 Samnakay N, Cohen RJ, Orford J, King PA, Davies RJ. Androgen and oestrogen receptor status of the human appendix testis. *Pediatr Surg Int* 2003; 19: 520–4.
- 11 Józsa T, Dienes B, Telek A, Hargitai Z, Pór Á, *et al.* Differential expression of androgen and estrogen receptor of appendix testis in patients with descended and undescended testes. *Int J Urol* 2008; 15:171–4.
- 12 Yamaguchi T, Nagata T, Hamasuna R, Osada Y. Indication for surgery of pediatric testicular and funicular hydroceles in view of natural course. *Nippon Hinyokika Gakkai Zasshi* 1996; 87: 1243–9.
- 13 Tanyel FC, Ocal T, Buyukpamukcu N. Excessive sac pressures: the pathogenesis and innocence of hydroceles in children. *BJU Int* 2001; 87: 372–5.

